

Insertion of a Double Lumen (Tracheobronchial) Tube

W. John Russell August 2005

The blind technique for insertion of double-lumen (tracheobronchial) tubes was described in 1992. Since then this technique has been modified and widely taught. There are several important steps in the effective use of this technique.

These are:-

- a) Recognition that the diameter of the bronchus (usually the left) is a crucial determinant of success. This size can be found from the standard P-A chest X-ray, which magnifies the air bronchogram by about 10% as the bronchi are about 6 inches from the plate which is positioned 6 feet from the X-ray source. Unfortunately the size in French gauge does not indicate the diameter of the bronchial segment of the tube. The table below gives a guide to the selection of the tube for the left main bronchus (taken from Russell WJ, Strong TS. Dimensions of double-lumen tracheobronchial tubes. *Anaesth. Intens Care* 2003; 31:50-53.)

Table 1 Relationship between left main bronchial measurement and tracheobronchial tube selection

	Measured Diameter of Left Main Bronchus on P-A Chest X-ray					
Measured (Actual) Diameter mm	9(8.1)	10(9.0)	11(9.9)	12(10.9)	13(11.7)	>14(12.6)
Sheridan	NA	28	-	35	37/39	41
Mallinckrodt	28	32	-	35	37/39	41
Portex	NA	NA	35	37	39/41	-
Riisch	NA	NA	NA	35	37/39	41

- b) Once the patient is anaesthetised and paralysed, the selected tube is inserted into the trachea until the bronchial cuff is about 3 cm below the vocal cords. This should leave the tube about 4-6 cm above its final position. Now the bronchial arm is connected directly to the anaesthetic circuit and BOTH lungs of the patient are ventilated through the bronchial tube. At this point the bronchial cuff is inflated in the trachea until the leak stops (Fig 1). This may take five mls of air or more

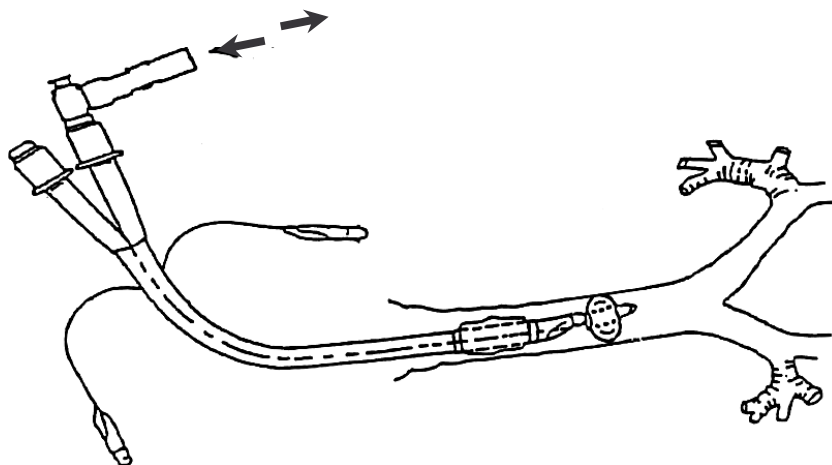


Figure 1. Double lumen tube with bronchial cuff inflated to firmly seal in the trachea. Both lungs are ventilated.

- c) With each breath, the tube is advanced slowly and gently down the trachea until the bronchial segment plugs the bronchus (Fig 2).

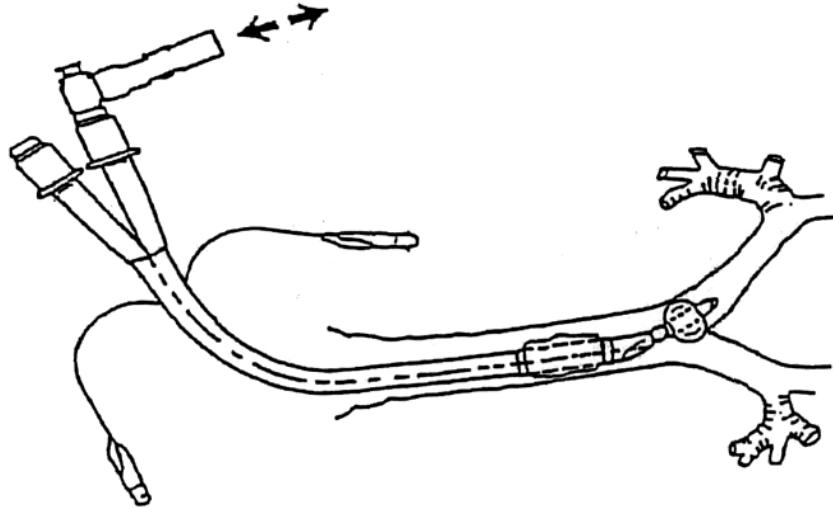


Figure 2. Double lumen tube with over-inflated bronchial cuff plugging the left main bronchus.

The endpoint signs are:

- 1) Resistance to further advancement (Good even with low-compliance lungs).
- 2) Unilateral ventilation by observation and by auscultation (Loss of breath sounds R side).
- 3) Reduction in compliance (Often best seen after a few breaths with IPPV on a ventilator).

- d) Once the bronchial plugging point has been identified, the cuff is deflated and the tube inserted an additional length (bronchial cuff length + 1 cm). The final bronchial cuff inflation to seal is then usually about 1 -2 ml. The patient connection is now changed to the tracheal connection and the tracheal cuff inflated until a seal is made in the trachea (Fig 3).

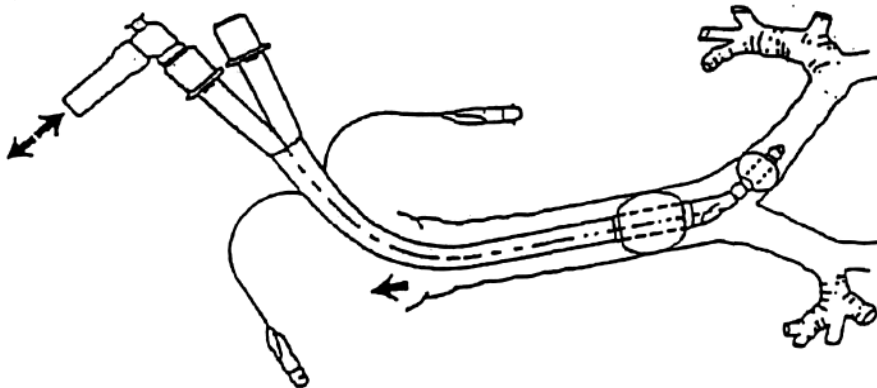


Figure 3 The double lumen tube in the final position in the left main bronchus with the bronchial and tracheal cuffs inflated

- e) If desired, further checks can be made by auscultation.

In a difficult case, the estimated length from plugging can be used for the final insertion even if the bronchial cuff has to be deflated to get the tube positioned into the left main bronchus. If a tube goes right, turning the head 90° so that the chin is on the right shoulder and rotating the tube on its long axis to restore the bronchial tube to point laterally, can usually achieve insertion into the left main bronchus. The distance inserted is then that previously determined from the right bronchial plugging.

It is also important to note the length of the Left main bronchus. If this is less than 4cm on the P-A chest X-ray, the length of the cuff and tip may be so long as to risk occluding the left upper lobe bronchus. It may be appropriate to check the position with a fibre optic bronchoscope. It may also be appropriate to select a smaller tube with a shorter cuff to give a better safety margin.